



PERFUSION CHANGES SECONDARY TO HEAVY METAL INTOXICATION DETECTED BY BRAIN PERFUSION SPECT IN CHILDREN WITH AUTISM.

**Cem KINACI, Serpilgul KINACI, Department of Nuclear Medicine,
 Alman Hospital, Deutsches Krankenhaus – Universal Hospitals Group**

Background: Autism is the most common of the pervasive developmental disorders. There are many theories as to the cause of autism such as abnormal cerebral blood flow to areas of the brain, high fevers, birth trauma, brain injury, infections, reactions to vaccines or lack of oxygen before, during or after delivery. There is an interplay between genes and environment. Human genome can be affected by nutrition. Genes can be turned on and off. Biochemical aftermath in autism spectrum disorders are impaired detoxification caused by undermethylation, remethylation defects, sulfation defects, cysteine deficiency and glutathione deficiency. Also heavy metal overload and oxidative stress caused by accumulation of toxic heavy metals, depletion of antioxidants, glutathione and metallothionein, mineral deficiency, mitochondrial dysfunction; gastrointestinal dysfunction and immune system dysregulation. Many cases of autism today are, in fact, cases of heavy metal poisoning. There is emerging evidence of neuroinflammation (1) and chronic blood-brain barrier dysfunction in these children. SPECT scanning can identify between recoverable brain cells (referred to as sleeping cells, idling neurons, or the ischemic penumbra) (2,3).

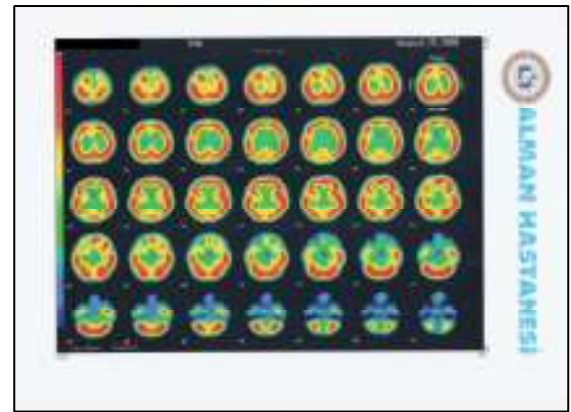
Materials: We performed a retrospective review between 2004-2008 in search of DMSA provoked urine toxic metals analyses, magnetic resonance imaging (MRI) and common functional abnormalities with brain perfusion single-photon emission computed tomography (SPECT) of 683 children (537 male, 146 female, between 1-18 years old) with autism and PDD.

Methods: Before the SPECT study was performed, the patients were placed in a quiet environment, an intravenous line was inserted, and ^{99m}Tc-HMPAO maximum 25 mCi (925 MBq) was administered a few minutes later. SPECT imaging was performed within 120 min after intravenous administration of the radiotracer. All of the acquisitions were performed under monitored sedation. A rotating, large-field of view gamma camera interfaced to a dedicated computer system was used. During a 360° rotation using a low-energy, high-resolution collimator 64 frames of images with a 128x128 matrix were acquired within 33 min. Total counts of 3.6-4 million were collected for each study. After image backprojection, image reconstruction was performed using a Butterworth filter (cut-off frequency 0.3).

Results: All of them have elevated or very elevated lead and 21.38% of them have elevated or very elevated mercury and some other toxic heavy metals such as nickel (14.05%), aluminum (6.00%), tin (3.51%), thallium (3.51%), arsenic (2.78%), tungsten (2.64%), uranium (2.49%) on their DMSA provoked urine toxic metal analyses. All of the patients had abnormal SPECT scans revealing focal areas of decreased perfusion. Decreased perfusion of temporal (45.66%), frontal (29.91%), primary motor cortex (8.20%), primary somatosensorial cortex (3.88%), basal ganglia (4.08%), parietal (5.02%), occipital (2.01%) and cerebellar (1.21%) areas were noted on brain SPECT. By contrast all patients had normal MRI findings.

Toxic Heavy metals	lead	mercury	nickel	aluminum	tin	thallium	arsenic	tungsten	uranium
% in patients	100.00	21.38	14.05	6.00	3.51	3.51	2.78	2.64	2.49

Decreased Perfusion Areas Detected by Brain SPECT Scans	temporal	frontal	primary motor cortex	primary somatosensorial cortex	basal ganglia	parietal	occipital	cerebellar
% in patients	45.66	29.91	8.20	3.88	4.08	5.02	2.01	1.21



Discussion: In conclusion, extensive perfusion impairments involving the temporal, frontal and primary motor cortex were found in this study. SPECT may be more sensitive in reflecting the pathophysiology of autism than MRI. However, further studies are necessary to determine the significance of brain perfusion impairment in autism. It is suspected by researchers that both genetic and environmental factors effect autism. They believe something they are exposed to in their environment triggers autism in some children. In our study, it is more than probable, the perfusion changes that we have seen at SPECT scans are secondary to heavy metal intoxication. DMSA provoked urine toxic metal analyses of these patients indicates this also.

References: (1) Diana L. Vargas, Caterina Nascimbene, Chitra Krishnan, Andrew W. Zimmerman, Carlos A. Pardo. Neuroglial Activation and Neuroinflammation in the Patients with Autism. *Ann. Neurol.* 2005 jan;57(1):67-81. (2) Starkstein S E, Vazquez S, Vrancic D, et al. SPECT Findings in Mentally Retarded Autistic Individuals. *J Neuropsychiatry Clin Neurosci* 2000;12:370-375. (3) Wilcox J, Tsuang M T, Ledger E, Algeo J, Schnurr T. Brain Perfusion in Autism Varies with Age. *Neuropsychobiology*, 2002;46:13-16.

**Autism
 Neuroscience
 Conference**

hosted by the Autism
 Research Centre (ARC),
 University of Cambridge

6th and 7th October 2008,
 The Royal Society, London,
 UK

